

# Global CNS gene transfer for a childhood neurogenetic enzyme deficiency: Canavan disease

Paola Leone, Christopher G Janson, Scott J McPhee & Matthew J During

## Address

CNS Gene Therapy Center  
Department of Neurosurgery  
Thomas Jefferson University  
Philadelphia  
PA 19107  
USA  
Email: Paola.Leone@mail.tju.edu

Current Opinion in Molecular Therapeutics (1999) 1(4):487-492  
© PharmaPress Ltd ISSN 1464-8431

*The neurogenetic prototypic disease on which we chose to test our gene therapy strategy is Canavan disease (CD). CD is an autosomal recessive leukodystrophy associated with spongiform degeneration of the brain. At present the disease is uniformly fatal in affected probands. CD is characterized by mutations in the aspartoacylase (ASPA) gene, resulting in loss of enzyme activity. In this review, recent evidence is summarized on the etiology and possible treatments for CD. In particular, we discuss two gene delivery systems representing recent advances in both viral and liposome technology: a novel cationic liposome-polymer-DNA (LPD) complex, DCCchol/DOPE-protamine, as well as recombinant adeno-associated virus (AAV) vectors.*

## Introduction and background

In our recent era of molecular medicine, physicians are compelled to think in terms of the genetic basis of disease, the expectation being that pathology can be ultimately explained as a collection of (genetically influenced) biochemical defects. CD, or *N*-acetyl aspartic acylase deficiency, is a fatal childhood leukodystrophy that is typified by lack of hydrolysis of *N*-acetyl aspartate (NAA), leading to a local build-up of NAA in the brain as well as a NAA acidemia and aciduria. It was first presented in a case report by Myrtelle Canavan in 1931 as a variant of Schilder's 'encephalitis periaxialis diffusa', a degeneration of the medullary sheaths with sparing of the axons. As it turns out the various cases described by Schilder were either multiple sclerosis, adrenoleukodystrophy, or subacute sclerosing panencephalitis [1], rather than CD and it was left to subsequent investigators to elucidate the distinctive morphological and biochemical profile of CD. With a better molecular understanding of disease processes and the advent of more effective experimental therapies, the past problems of identification and poor prognosis will greatly improve.

The original Canavan patient presented with vomiting, constipation, and lack of proper weight gain; the child failed to meet developmental milestones such as grasping at objects or holding up its head; the cranium grew progressively and disproportionately large; vertical nystagmus and a convergent strabismus were noted; the initial hypotonia was later followed by symptoms of hyper-reflexia. When the child died at age 16 months, an autopsy demonstrated subcortical loss of myelin and diffuse and marked edema of the white matter [2]. The distinctive spongiform pathology of the brain in CD, said to resemble 'a sponge soaked with water' [3], was later clarified in the

literature by Van Bogaert and Bertrand [4]. The biochemical defect common to all CD patients, however, was not discovered until 1988, when Matalon and coworkers discovered the mutant aspartoacylase (ASPA) enzyme [5]. Although the *ASPA* gene was cloned in 1993 and the most common mutations have now been isolated [6], the cellular pathology that results in CD has yet to be elucidated and the contribution of the substrate molecule (NAA) is still unclear.

## Symptoms and pathology

Many symptoms of CD are common to other organic acid disorders and include megalencephaly, ataxia, myoclonus and extrapyramidal symptoms (hypotonia, dystonia and dyskinesia) [7]. The typical progression of extrapyramidal signs is hypotonia followed by a gradual increase of tone, leading eventually to rigidity, spasticity and choreoathetosis. In addition, there is usually considerable psychomotor and mental retardation, manifested by apathy and a failure to meet developmental milestones. Partial or grand mal seizures are also common, and in studies by Traeger and Rapin, 63% of CD patients had some form of epilepsy [8]. Certain features of CD such as macrocephaly, mental retardation, spasticity and optic atrophy are found in other leukodystrophies, such as Tay Sach's and Alexander disease.

Apart from the elevation of NAA, which is unique to CD, the characteristic 'spongy' degeneration in CD is the most unusual feature of the pathology. A similar morphological change can occur after exposure to certain toxins (eg, triethyl tin, cuprizon, iproniazid). The first ultrastructural study was published by Adachi in 1966, and demonstrated large spaces within the myelin sheaths, as well as swollen astrocytic cells and processes [9]. Others have noted a loss of demarcation of the cortical white and grey matter, with multiple vacuoles (up to 200 µm in diameter) throughout the deep cortex and subcortical white matter. The spongy pathology is characterized by an accumulation of excessive fluid mainly within the myelin lamellae and astrocytic processes [10]. Elongated mitochondria are typically observed in the astrocytes. The nuclei and cell bodies of neurons are generally intact without evidence of abnormality [9]. Vacuolated oligodendrocytes are seen occasionally, but most oligodendroglia are normal even in areas of expanded extracellular space and disintegrating myelin sheaths. In the cortex, the 'sponginess' was found in one study to correspond to swollen astrocytes, whereas in white matter the vacuoles were formed by the intramyelinic and extracellular fluid (ECF) [11]. In general the entire central nervous system (CNS) is affected, with vacuolization of white matter most evident in the cerebellum and brainstem [12].

## The relationship of NAA and ASPA to the disease pathology

It is interesting that NAA is strictly compartmentalized within the brain. NAA is synthesized only in the CNS, and more specifically only within the mitochondria of neurons

[13•,14]. It is found in high concentrations within neurons (5 to 10 mM) and it has long been considered a neural-specific marker. On the other hand, ASPA has a wide tissue distribution and it has been isolated from human kidney, adrenal glands, lung, liver and skin [15••]. Within the brain, ASPA is predominantly localized to the white matter, where it is found in highest concentration among the axons and myelin [16]. It has been reported that ASPA in gray matter and blood components is undetectable [17]. This fact is significant, because bone marrow transplant (BMT) has been suggested as a possible ameliorative measure to lower NAA in CD, and a patient recently received a BMT in the hope of lowering systemic NAA [Krivit W, personal communication]. BMT has been used in a number of other CNS leukodystrophies [18], but its relevance in CD is unknown.

Interstitial levels of both NAA and NAAG (*N*-acetyl-aspartyl-glutamate, a biosynthetic product of NAA) are elevated in CD. Neurons have a several-fold increased level of NAA over white matter and yet the gray matter is spared significant pathological change in CD, which argues against a directly toxic role of NAA in the pathogenesis. However, one hypothesis has been that high levels of NAA may be toxic when applied to glial cells, yet neuronal cells are spared. Studies on NAA and NAAG, demonstrate limited binding to NMDA receptors and suggest the possibility of toxic effects on neurons *in vitro* [19]; relatively low levels (approximately 1 mM) of either NAA or NAAG are not neurotoxic when applied to neuronally-enriched cell culture [20], but higher levels of NAA (approximately 3 to 10 mM) can elevate intracellular calcium up to 3-fold [21]. Some glial cells are known to be susceptible to glutamate excitotoxicity, but the fact that ultrastructural studies have shown limited oligodendrocyte cell body involvement in CD argues against a simple cytotoxic hypothesis of NAA or NAAG for those cells.

The normal function of NAA has been debated for some time. It has been suggested that a main role is as an acetyl donor in lipogenesis. The acetyl group of NAA is incorporated into a variety of lipids in brain and liver; it is converted to acetate and acetyl-CoA in both tissues [22]. Therefore one hypothesis is that NAA functions as a storage form of acetate and for acetyl-CoA production. The implication for CD is that a decrease in available acetyl-CoA (through a failure of ASPA to cleave NAA) would lead to a failure of acetyl-CoA requiring reactions. This would explain the apparent demyelination of CD [14]; however, it does not specifically account for the spongiform changes.

Another hypothesis of normal NAA function is that it functions as part of an osmotic (water) pump. Through comparative anatomical studies of fish, amphibians, and mammals, Baslow concluded that unhydrolyzed NAA in the ECF functions as an 'osmolar diuretic' to draw out water, which can congest the axons and disrupt the myelin sheaths without destroying the axons [13•]. Although the mechanism was unclear at the time, the idea of water imbalance causing demyelination was proposed back in the 1960s. Van Bogaert and Bertrand advanced this hypothesis, in which they noted that "retention of water in the nervous tissue breaks up the normal myelin and edema in areas of intact myelin may destroy the latter...

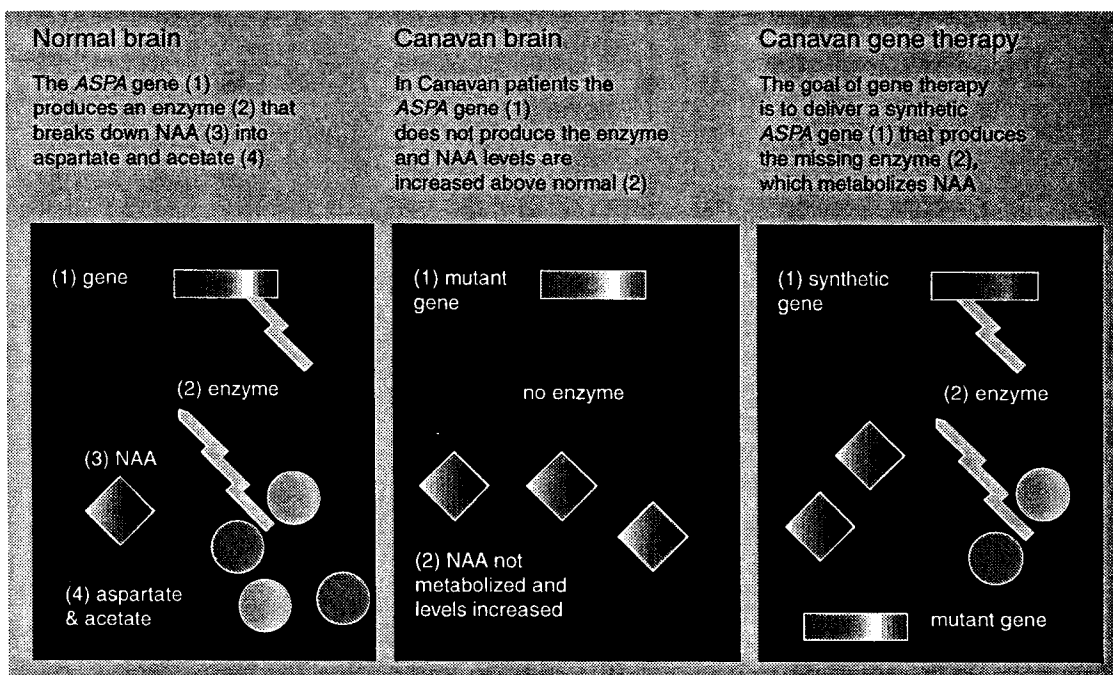
the edematous swelling can precede the demyelination: one imagines in fact that the myelin destruction may result from the spongy swelling" [3]. More recently, *in vivo* microdialysis experiments have been performed in rats that support an osmoregulatory role for NAA, in which step exposure to hyposmotic media increases dialysate levels of NAA [29•].

Baslow has suggested that NAA, NAAG, carnosine and homocarnosine "probably have a common function as regulators of cellular water efflux" [16]. When this water efflux is accentuated through a failure of NAA degradation in the extracellular space, intramyelinic swelling typical of CD may result. Baslow has additionally proposed a transcellular flow, driven by NAA efflux and breakdown, with the maintenance of a high tissue-to-ECF gradient of NAA and a continuous NAA efflux into the ECF. This model predicts a mild aspartate deficit in CD caused by a failure to degrade NAA. Baslow has described a 'near-field' and a 'far-field' cycle for NAA. The purpose of the far-field cycle would be to transport aspartate from the periphery, perhaps using erythrocytes (which concentrate aspartate) as a vehicle. The lack of CD pathology *in utero* is attributed to the protective effect of the maternal circulation, which supplies aspartate to the fetus. If hypo-aspartia indeed constitutes an important aspect of the pathology, this model predicts that infusion of aspartate into ASPA-deficient animals or humans might be beneficial if higher, but non-toxic levels within the CNS are maintained [13•]. It has been suggested by a number of investigators that a state of hypo-aspartia induced by failure of the normal NAA cycle might lead to a decreased generation of oxaloacetate (the rate-limiting substrate for the tricarboxylic acid cycle) through a decrease in transamination reactions, which could in turn disrupt cellular metabolism; research groups are currently collaborating with Keith Hyland to quantify (using HPLC techniques) cerebroventricular metabolites that may support or disprove this hypothesis.

The idea of osmolar disequilibrium as an underlying cause of edema in CD is not new. Some researchers have looked specifically at Na<sup>+</sup>/K<sup>+</sup> transporters, given a similar spongiform pathology that occurs as a result of treatment in experimental animals with ouabain, which blocks the Na<sup>+</sup>/K<sup>+</sup> transporter and causes pathological swelling of astrocytes and presynaptic axon terminals [9]. Yet there appears to be no pathology specific to these transporters. In spongy degeneration the synapses display a normal ATPase activity and the axon terminals are unchanged; however, the mitochondrial ATPase activity is somewhat decreased, perhaps a marker of overstrained mitochondria and a possible cause of the typical astrocytic swelling [9]. The abnormal mitochondrial ultrastructure in CD tends to suggest a role for metabolic or energetic causes in the pathogenesis of CD, and it is possible that water imbalance acts to exacerbate co-existing metabolic or energetic problems.

In summary, there are several possible theories of the normal role of NAA (lipid biosynthesis precursor, TCA intermediate and osmolyte) and its role in the pathology of CD when ASPA is deficient (cytotoxic, metabolic and osmotic). The relative importance of each of these factors, and how they may work together, has yet to be determined.

Figure 2. Schematic representation of the gene therapy trial.



In these two patients, activity of ASPA in skin fibroblasts was only 4 to 5% of wild-type, yet the children had minimal leukodystrophy at the ages of 2 and 4 years. It is possible that this milder phenotype, in which brain NAA elevation is less pronounced and symptoms are delayed, may be reproduced by overexpressing ASPA in the brain.

Despite the hurdles that the brain poses for gene therapy, significant advances have been made in two delivery systems (liposomal and viral) for gene transfer to the CNS. The first is a second generation, liposome-based delivery system based on the DC-Chol/DOPE together with protamine as a DNA-condensing agent. The most recent is recombinant AAV vector: a defective, human non-pathogenic parvovirus. It has been shown that AAV can safely and effectively transduce mammalian neurons and glia, and in a rodent model of Parkinson's disease, long-term phenotypic correction has been shown [30••]. Furthermore, as AAV is extremely small (only 20 nm), using strategies to modify the blood-brain barrier it may more readily cross into and through the brain parenchyma.

Over the past 5 years, investigators have generated sufficient safety data in rats and primates to achieve approval for two clinical phase I studies (University of Auckland, New Zealand and Yale University/Thomas Jefferson University, USA) for ASPA gene therapy in children affected by CD (Figure 2); the development of a homologous knockout mouse model of CD is still in progress, and therefore no efficacy data could be generated at the time that the clinical studies were first approved. An ASPA-expressing plasmid with the transcription unit flanked by AAV-inverted terminal repeats (ITRs) was constructed and tested *in vitro* for ASPA expression, and high levels of enzyme activity were obtained; this plasmid was then used in a non-viral vector complex for animal expression and toxicity studies. ASPA transgene expression was observed at the level of mRNA using reverse transcriptase

(RT)-PCR with primers specific to the vector-encoded ASPA. There is still no monoclonal antibody to ASPA, and therefore detection at the protein level was not possible, except for fusion gene constructs.

As a delivery method, a novel liposome-encapsulated, condensed plasmid DNA (LPD) was chosen [26]; the expression plasmid consisted of the early cytomegalovirus (CMV) promoter, the human aspartoacylase (ASPA) full-length cDNA and a SV40 polyA flanked by AAV 145 base pair ITRs. The LPD complex was designed to be delivered into the cerebral ventricles, the rationale being that a large surface area of brain tissue could be transduced if the vector penetrated the ependymal cells. Results in animals showed expression in ependyma (periventricular cells) with some limited expression extending into parenchyma. The liposome used in the gene therapy trials was originally synthesized in January 1992 at the University of Pittsburgh and was the same batch used for other gene therapy phase I trials [27,28]. Poly-L-lysine was used as a cationic polymer during the first gene therapy trial in New Zealand in two children, and protamine in 14 children during the phase I trial in the USA.

This intervention represented the first human gene therapy trial for a neurodegenerative disease, and an important 'proof-of-principle' study of an otherwise fatal disease. Initial results appear promising, bearing in mind that the endpoints of phase I studies are those of safety and tolerability. Following the demonstration of safety, efforts are being directed towards further defining the efficacy of this treatment, using a number of clinical outcome measures: CSF analysis, MRI (myelin quantification), <sup>1</sup>H-NMR spectroscopy (NAA quantification), evoked potentials (auditory, visual, somatosensory and brainstem), neurological evaluation, and parental reports with videotapes. Preliminary (unpublished) data using AAV-ITR-

## Prenatal diagnosis

CD is associated with a marked increase in NAA levels in cerebral spinal fluid (CSF), plasma and urine. This biological marker became the primary method of diagnosis following identification of ASPA deficiency in the late 1980s [5•]. Prior to that time, surgical brain biopsy in conjunction with computed tomography (CT) was the best method for diagnosis. Prenatal genetic counseling and testing is now available for CD, and is recommended for Ashkenazi Jewish descendants (who have a carrier frequency of approximately 1 in 40) and all other patients in a high-risk group. Polymerase chain reaction (PCR)-based genetic testing is available for well-characterized mutations.

## Canavan disease and symptomatic therapies

The severity of CD symptoms varies significantly on a case by case basis. The clinical course of the disease is relentlessly progressive, although the rate of deterioration is variable. At present there is no treatment of proven efficacy, although gene therapy seems to be the most promising approach, particularly as vector design and delivery improves (Figure 1). Current management is based on a combination of physiotherapy procedures and supportive strategies such as dietary modifications (eg, ketogenic diet), nutritional supplements (eg, carnitine, calcium acetate) and palliative drug regimens such as anti-epileptics, anxiolytics and diuretics.

Calcium acetate (15 to 30 mg/kg per day) and acetazolamide (5 to 7 mg/kg per day) administration may be indicated in CD. Controlled studies have not yet been performed, but there is anecdotal evidence suggesting that combination of these two drugs is associated with improvements in neurological function in children with CD [Kolodny E, personal communication]. The calcium acetate (PhosLo) was originally given to CD patients to control hyperphosphatemia, and was incidentally found to improve mental function, possibly through increased lipid synthesis; the diuretic is intended to decrease ECF in the brain.

Another possible therapeutic approach might include the use of the recombinant ASPA enzyme delivered directly into the brain of children with CD. This approach has not been developed sufficiently to demonstrate all the risks (in addition to surgery), but based on the outcome of an Israeli trial on brain delivery of hexaminadase A to children with Tay Sach's disease, such an approach is unlikely to afford adequate or long-term benefits [23].

## Canavan disease and gene therapy

Considered together, the leukodystrophies are attractive candidates for replacement gene therapy, considering the catastrophic effects of the diseases, the absence of other effective treatments and the fact that a single gene etiology has been identified for a number of these disorders. CD as a target is particularly attractive because the pathology is restricted to the brain rather than being multi-systemic, and the effect of gene transfer (ASPA delivery) can be followed non-invasively using <sup>1</sup>H-NMR of brain NAA levels.

There are a number of obstacles to effective AAV-mediated ASPA gene therapy, among them the problem of targeting all the affected cells and achieving sufficiently long-term levels of gene expression. On the bright side, it is possible that only a small fraction of transduced cells might correct the abnormal ASPA function in CD patients. Studies of heterozygote carriers of ASPA mutation alleles demonstrated that ASPA activity in fibroblasts might be only 40% that of non-carriers, yet heterozygotes have no phenotype [24•]. Therefore even modest gains in enzyme activity may be sufficient to lower NAA and to have an effect on the disease course. In addition, there is a late-onset variant of CD (onset of severe symptoms after the age of 5 years) with less elevation of NAA in the brain, which is hypothesized to have a milder ASPA defect than the early-onset CD patients. In two children with this juvenile form of the disease, urine NAA levels were elevated, but CNS levels of NAA were initially normal as measured by <sup>1</sup>H-NMR [25•].

**Figure 1.** The first four children with Canavan disease enrolled in the gene therapy phase I trial (post-gene delivery).



based condensed plasmid vectors suggest that non-viral, *in vivo* gene therapy of CD is safe and may be associated with some biochemical, radiological and clinical benefit. Currently our efforts are focused on the improvement and testing of high-titer, ultrapure ASPA-AAV viral vectors for use in future clinical trials. The original phase I safety trial is ongoing in terms of data collection, but has paused in terms of vector administration, in order to accommodate vector improvements and testing; it is hoped that new AAV vectors, driven by a variety of brain-specific promoters, will afford greater long-term expression of the deficient enzyme.

## Conclusion

CD is a noteworthy and tragic disease, yet the importance of this study extends well beyond CD. Progress toward safe and effective gene therapy will help in the development of better treatments for a host of other neurological disorders, whether lysosomal, peroxisomal, metabolic or multifactorial. This century has seen ground-breaking medical discoveries, which have uncovered the biochemical pathways as well as the genetic identity underlying many diseases; the crucial steps involved in designing an effective gene-based therapy include determining the function of the key gene products associated with a given disease, identifying and characterizing the relevant genes, and finally manipulating them at will with the aid of new generation delivery vectors. This is the ultimate goal and challenge of gene therapy: to make biochemistry the servant of our genetic interventions.

## References

- of outstanding interest
  - of special interest
1. Prineas JW, McDonald WI: **Demyelinating diseases.** In: *Greenfield's Neuropathology (Vol 1)*. Graham DI, Lantos PL (Eds), Arnold, London (1997):853.
  2. Canavan MM: **Schilder's encephalitis periaxialis diffusa.** *Arch Neurol Psychiatry* (1931) 25:299-308.
  3. Van Bogaert L, Bertrand I: **Spongy degeneration of the brain in infancy.** Charles C Thomas, Amsterdam (1967).
  4. Van Bogaert L, Bertrand I: **Sur une idiote familiale avec degenerescence spongileuse de neuraxe (note preliminaire).** *Acta Neurol Belg* (1949) 49:572-587.
  5. Matalon R, Michals K, Sebesta D, Deanching M, Gashkoff P, Casanova J: **Aspartoacylase deficiency and N-acetylaspartic aciduria in patients with Canavan disease.** *Am J Med Genet* (1988) 29:463-471.
    - The first study to demonstrate that ASPA deficiency is the main biochemical defect in CD.
  6. Matalon R, Kaul R, Michals K: **Canavan disease: biochemical and molecular studies.** *Inherit Metab Dis* (1993) 16(4):744-752.
  7. Hoffmann GF, Gibson KM, Trefz FK, Nyhan WL, Bremer HJ, Rating D: **Neurological manifestations of organic acid disorders.** *European J Ped* (1994) 153:S94-100.
  8. Traeger EC, Rapin I: **The clinical course of Canavan disease.** *Ped Neurol* (1998) 18:207-212.
  9. Adachi M, Schneck L, Cara J, Volk BW: **Spongy degeneration of the central nervous system (van Bogaert and Bertrand type; Canavan's disease).** *Hum Pathol* (1973) 4:331-347.
  10. Gambetti P, Mellman WJ, Gonatas NK: **Familial spongy degeneration of the central nervous system (Van Bogaert-Bertrand disease). An ultrastructural study.** *Acta Neuropathol (Berl)* (1969) 12:103-115.
  11. Adomato BT, O'Brien JS, Lampert PW, Roe TF, Neustein HB: **Cerebral spongy degeneration of infancy. A biochemical and ultrastructural study of affected twins.** *Neurology* (1972) 22:202-210.
  12. Sacks O, Brown WJ, Aguilar MJ: **Spongy degeneration of white matter: Canavan's sclerosis.** *Neurology* (1965) 15:2165-2171.
  13. Baslow MH: **The existence of molecular water pumps in the nervous system: A review of the evidence.** *Neurochemistry International* (1999):77-90.
    - Hypothesis about the normal function of NAA as part of an osmotic (water) pump.
  14. Mehta V, Namboodiri MA: **N-acetylaspartate as an acetyl source in the nervous system.** *Brain Res Mol Brain Res* (1995) 31:151-157.
  15. Kaul R, Gao GP, Balamurugan K, Matalon R: **Cloning of the human aspartoacylase cDNA and a common missense mutation in Canavan disease.** *Nature Genet* (1993) 5:118-123.
    - Original cloning of ASPA and analysis of CD mutation.
  16. Baslow MH: **Molecular water pumps and the aetiology of Canavan disease: A case of the sorcerer's apprentice.** *J Inherit Metab Dis* (1999) 22:99-101.
  17. Matalon R, Michals K, Kaul R: **Canavan disease: from spongy degeneration to molecular analysis.** *J Ped* (1995) 127:511-517.
  18. Krivit W, Peters C, Shapiro EG: **Bone marrow transplantation as effective treatment of CNS disease.** *Curr Opin Neurol* (1999) 12(2):167-176.
  19. Pai KS, Ravindranath V: **Toxicity of N-acetylaspartylglutamate and its protection by NMDA and non-NMDA receptor antagonists.** *Neurosci Lett* (1991) 126:49-51.
  20. Burlina AP, Skaper SD, Mazza MR, Ferrari V, Leon A, Burlina AB: **N-acetylaspartylglutamate selectively inhibits neuronal responses to N-methyl-D-aspartic acid *in vitro*.** *J Neurochem* (1994) 63:1174-1177.
  21. Rubin Y, LaPlaca MC, Smith DH, Thibault LE, Lenkinski RE: **The effect of N-acetylaspartate on the intracellular free calcium concentration in NTER2-neurons.** *Neurosci Lett* (1995) 198:209-212.
  22. Tallan HH, Moore S, Stein WH: **N-Acetyl-L-aspartic acid in brain.** *J Biol Chem* (1956) 219:257-264.
  23. von Specht BU, Geiger B, Aron R, Passwell J, Keren G, Goldman B, Padeh B: **Enzyme replacement in Tay-Sachs disease.** *Neurology* (1979) 29(6):848-854.
  24. Barash V, Fihor D, Morag B, Boneh A, Elpeleg ON, Gilon C: **A radiometric assay for aspartoacylase activity in human fibroblasts: application for the diagnosis of Canavan's disease.** *Clinica Chimica Acta* (1991) 201(3):175-181.
    - Aspartoacylase activity in cultured human fibroblasts from CD homozygotes, CD heterozygotes and control patients.
  25. Toft PB, Geiss-Holtorf R, Rolland MO, Pryds O, Muller-Forell W, Christensen E, Lehnert W, Lou HC, Ott D, Hennig J: **Magnetic resonance imaging in juvenile Canavan disease.** *Eur J Ped* (1993) 152:750-753.
    - Report on two patients with a mild juvenile form of CD with elevated urine NAA concentration, normal NAA level in the brain and milder phenotype.

26. Gao X, Huang L: **Potential of cationic liposome-mediated gene delivery by polycations.** *Biochemistry* (1996) **35**(3):1027-1036.
27. Perez-Soler R, Shin DM, Siddik ZH, Murphy WK, Huber M, Lee SJ, Khokhar AR, Hong WK: **Phase I clinical and pharmacological study of liposome-entrapped NDDP administered intrapleurally in patients with malignant pleural effusions.** *Clin Cancer Res* (1997) **3**:373-379.
28. Caplen NJ, Alton EW, Middleton PG, Dorin JR, Stevenson BJ, Gao X, Durham SR, Jeffery PK, Hodson ME, Coutelle C: **Liposome-mediated CFTR gene transfer to the nasal epithelium of patients with cystic fibrosis [published erratum appears in *Nat Med* (1995) 1(3):272].** *Nature Med* (1995) **1**:39-46.
29. Taylor DL, Davies SEC, Obrenovitch TP, Doheny MH, Patsalos PN, Clark JB, Symon L: **Investigation into the role of N-acetylaspartate in cerebral osmoregulation.** *J Neurochem* (1995) **65**(1):275-281.
  - *Support for the function of NAA in osmoregulation, suggesting that the vacuolar disease pathology may be potentially reversed by addressing NAA balance through (gene therapy) enzyme correction.*
30. Kaplitt MG, Leone P, Samulski RJ, Xiao X, Pfaff DW, O'Malley KL, During MJ: **Long-term gene expression and phenotypic correction using adeno-associated virus vectors in the mammalian brain.** *Nature Genetics* (1994) **8**:148-154.
  - *This was the first paper showing expression of a transgene using AAV in the brain and phenotypic correction of a neurodegenerative disease, which formed a basis for other brain interventions including the Canavan project.*